

Case Report

Purpura: A Rare Presentation of Endocarditis to Keep In Mind

Sara Belabyad*, Joumana El Masrioui, Sara Jourani, Mohammed El Jamili, Dounia benzeroual, Saloua El Karimi and Mustapha El Hattouai

Cardiology Department, Mohammed VI University Hospital, Marrakesh, Morocco

*Corresponding Author
Sara Belabyad

Article History: | Received: 05.02.2020 | Accepted: 14.02.2020 | Published: 28.02.2020 |

Abstract: Infective endocarditis, characterized by microbial infection of the endothelial surface of the heart, can have numerous symptoms and signs. Typically they include fever, chills, a new or changing heart murmur, and bacteremia. Infective endocarditis can appear in an atypical manner and pose a diagnostic challenge. In such cases, initial signs and symptoms might be those from a complication. Purpura is a rare occurrence in the course of bacterial endocarditis but may be a prominent sign of this disease. This report concerns a patient with streptococcal infection of the mitral valve, who presented with such striking purpura that the possibility of a primary coagulation disorder was seriously considered before the diagnosis of bacterial endocarditis was established.

Keywords: Infective endocarditis, cutaneous vasculitis, purpura.

Copyright @ 2020: This is an open-access article distributed under the terms of the Creative Commons Attribution license which permits unrestricted use, distribution, and reproduction in any medium for non commercial use (NonCommercial, or CC-BY-NC) provided the original author and source are credited.

INTRODUCTION:

Infective endocarditis (IE) is a disease with high morbidity and mortality, often presented as a multisystemic disease. Its heterogeneous features present a diagnostic challenge. According to the literature, the frequency of skin lesions in patients with definite IE who had dermatological manifestations varies widely (5-25% of IE cases) across investigations. None is pathognomonic for endocarditis (Tous-Romero, F. *et al.*, 2017 ; & Habib, G. *et al.*, 2009).

It is important to know and identify these skin manifestations associated with infective endocarditis, given the importance of reaching an early diagnosis and the prognostic implications associated with their appearance (Tous-Romero, F. *et al.*, 2017).

We describe a case of cutaneous vasculitis as a primary manifestation leading to the diagnosis of infectious endocarditis.

CASE REPORT:

A 60 years old female with no history of valvular disease developed on-and-off fever, malaise, bilateral upper and lower extremity rash (Fig 1), shortness of breath and palpitation two weeks before

her admission. She was in a good shape before these symptoms. She had no history of hypertension, diabetes mellitus, smoking or drug addict.

On presentation, the patient's vital signs were: blood pressure 125/75 mmHg, heart rate 113 bpm, respiration rate 20 breaths/min, saturating 95% on room air and body temperature was 39.5°C. On physical exam, auscultation showed a systolic murmur in the mitral focus at 3/6, the lungs were clear. Her abdomen was soft and nontender. Bowel sounds were present; abdominal palpation found no hepatosplenomegaly. Her extremities showed no edema, clubbing, or cyanosis, and pulses were present and symmetrical. She had 5/5 strength in all four extremities, with normal sensation.

In the emergency department laboratory studies disclosed the following values: white cell count 22000 /L (48% neutrophils), hemoglobin 12.6 g/dL, hematocrit of 30.6%, and platelet count 250000 /L. The coagulation time, clot retraction, and bleeding time was normal. Blood urea was 0.24 g/L and creatinine was 9.4 mg/L, similar to her baseline renal function studies. The level of C-reactive protein was raised to 320 mg / l (normal <5 mg / l).

A transthoracic echocardiography (TTE) was performed and revealed an echogenic mass in the mitral valve, suggestive of vegetative growth (Fig 2), with moderated mitral insufficiency. Blood cultures were positives to beta hemolytic streptococcus.

The patient was admitted to the medical ward with a diagnosis of infective endocarditis (IE). She was treated with antibiotics.

The fever subsided after 48 hours of antibiotics and laboratory results showed a gradual improvement in leukocytosis and the level of reactive protein C. She was released and was to be followed on an outpatient basis.

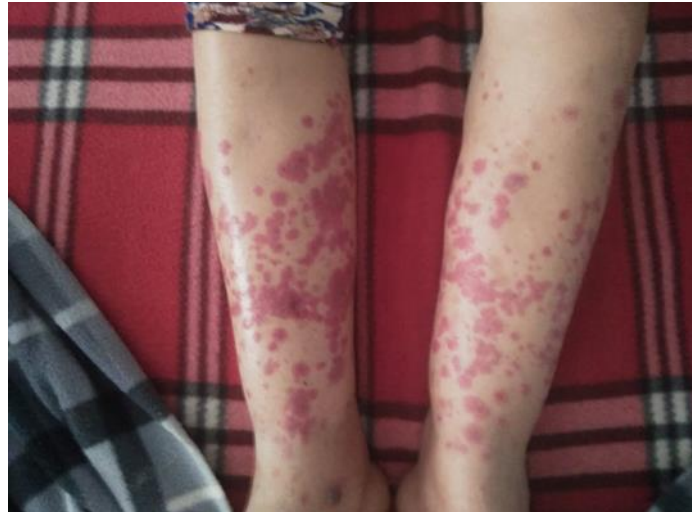

Fig 1: A physical examination revealed a purpuric rash over the entire surface of both legs.

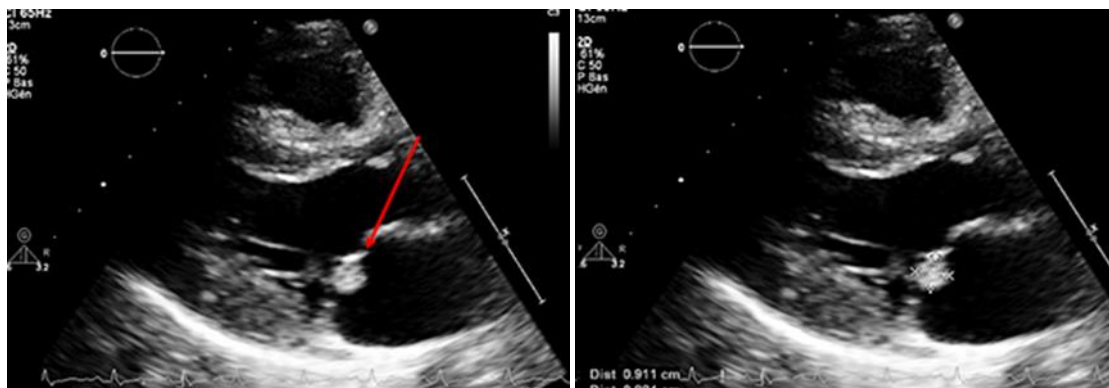


Fig 2: Parasternal long axis view showing vegetation in the mitral valve leaflet

DISCUSSION:

The overall incidence of infective endocarditis is 1.7 to 4.0 per 100,000 population (Conti, T., & Barnet, B. 2001; & Cunha, B. A. *et al.*, 1996). In patients older than 50 years, the incidence of infective endocarditis exceeds 15 per 100,000 population (Conti, T., & Barnet, B. 2001; & Cunha, B. A. *et al.*, 1996).. In addition to age, other risk factors include male gender, congenital and rheumatic heart disease, mitral valve prolapse, prosthetic valves, previous occurrence of infective endocarditis, intravenous drug use, and nosocomial instrumentation (Conti, T., & Barnet, B. 2001; & Karchmer, A. W. 1998).

Numerous microbial organisms with variable virulence can cause infective endocarditis. *S aureus* is

the most common etiologic organism (Conti, T., & Barnet, B. 2001; & Cunha, B. A. *et al.*, 1996).

Signs and symptoms of infective endocarditis result from either local destructive effects of the cardiac endothelial surface, metastatic embolization of infected fragments to distant sites, hematogenous seeding of other sites, or antibody formation and deposition of immune complexes in tissues (Conti, T., & Barnet, B. 2001).

IE is often a challenging condition to diagnose, as the symptoms of IE are diverse and non specific. The classical triad of fever, anemia and heart murmur is uncommon. Patients may also present in an atypical manner resulting from complications of IE such as pneumonia, meningitis, congestive heart failure,

osteomyelitis, septic arthritis, glomerulonephritis, endophthalmitis, splenic infarction, or vasculitis, and can take away the attention from the underlying cardiac cause. Such complications initially might obscure the diagnosis of endocarditis (Lee, G. P. C. *et al.*, 2009; & Karchmer, A.W. 1997).

The Duke criteria, proposed by Durack and al in 1994 (Durack, D. T. *et al.*, 1994), using echocardiographic data along with clinical, microbiologic and pathologic findings, provide a sensitive and specific approach to diagnose IE (Lee, G. P. C. *et al.*, 2009).

Transthoracic echocardiography (TTE) is rapid and non invasive, and it has excellent specificity for vegetations. Depending on the population studied, TTE has been reported to have a sensitivity of 40-80% for the detection of vegetations (Mylonakis, E., & Calderwood, S. B. 2001). Because of the possibility of a false negative (or the absence of a vegetation) or a false positive examination (Lamb's excrescences, non infective vegetation or thrombi), TTE should not supplant clinical and microbiological diagnosis. TTE views may be inadequate in up to 20% of adult patients because of technical imaging difficulties including obesity, chronic obstructive pulmonary disease, or chest wall deformities. As a result, TTE alone cannot exclude IE confidently in case of suspicion (Lee, G. P. C. *et al.*, 2009).

In the pathogenesis of IE, predisposing conditions like abnormalities in endocardial structures or decreased host immunity are usually required for the initiation of endocarditis. Regions exposed to turbulent flow result in endothelial damage. It will lead to activation of circulating platelet activators, localised platelet and fibrin deposition, formation of sterile thrombus, and subsequent colonisation by microorganisms. (Lee, G. P. C. *et al.*, 2009).

The association of purpura with infection has been known since the middle ages, when it frequently occurred in the course of plague, typhus, and other Pestilential fevers which repeatedly swept through Europe in epidemics (Horwitz, L. D., & Silber, R. 1967; & Jones, H. W., & Tocantins, L. M. 1933). The first report of purpura in SBE was by F. Parkes Weber in 1910 (Weber, F. P. 1910). A second case was described by Osier in 1912 (Osler, W. 1912).

Although generalized purpura is rare in bacterial endocarditis, petechiae are common. Whether purpuric spots are merely enlarged petechiae or an entirely different mechanism is involved in their appearance in infection is unknown. Bacterial endocarditis can cause thrombocytopenia of sufficient severity to give rise to skin hemorrhages, but significant decrease in the number of platelets was not present in the case reported above and is not a factor in many

other instances of purpura secondary to infectious diseases (Stefanini, M., & Dameshek, W. 1955; & Wintrobe, M.M. 1961). Toxic damage to vascular endothelium is the usual explanation given for the non thrombocytopenic purpura of bacterial endocarditis and other infections (Wintrobe, M.M. 1961). Some regard emboli to small vessels and consequent diminished blood supply to the involved area of skin as the major factor (Stefanini, M., & Dameshek, W. 1955).

Supporters of the embolic theory cite frequent instances in which purpuric spots due to infection have necrotic white centers which are presumed to be related to greater ischemia in the area most dependent on blood supply from the occluded vessel (Stefanini, M., & Dameshek, W. 1955). These were not seen in the purpuric spots of the patient described above. Libman and Friedberg considered purpura to be a feature of a "bacteria-free" stage of bacterial endocarditis in which there is no active infection present, and skin hemorrhages are caused by sterile calcific emboli thrown off from the involved valve (Libman, E., & Friedberg, C. K. 1941). The patient described in this paper, however, had positive blood cultures during the purpuric phase.

In our case, the normal coagulation time, the retraction of the clot, the platelet count and the bleeding time suggest the presence of an essentially normal coagulation mechanism.

Purpura in a patient with normal bleeding and clotting times, normal platelet count and negative tourniquet test leads to consideration of infection, Henoch-Schonlein purpura, dysglobulinemia or toxic chemicals as possible etiologies. Infectious causes include infective endocarditis, meningococemia, typhoid fever, tuberculosis, rickettsial diseases, diphtheria, staphylococemia, scarlet fever, and some viral exanthems (Stefanini, M., & Dameshek, W. 1955 ; Wintrobe, M.M. 1961 ; Libman, E., & Friedberg, C. K. 1941 ; & Bauch, S. 1916).

In our patient, a combination of fever, heart murmur and cutaneous vasculitis leads to the suspicion of IE. However, the patient did not have any predisposing factors for IE. TTE provided additional information to support the diagnosis.

Finally, the cardiac murmur detected on the physical examination may have been a cue to diagnose infective endocarditis in this case. Detecting the murmur led to finding the vegetative growth on echocardiography . These findings suggest that clinical suspicion after a physical examination is important to diagnose infective endocarditis

CONCLUSION:

In a purpuric patient, fever, heart murmurs, or other cardiac findings, splenomegaly, clubbing, or

evidence of peripheral embolization should alert the clinician to the possibility of infective endocarditis.

It is important to know and identify those manifestation associated with infective endocarditis, given the importance of reaching an early diagnosis and the prognostic implications associated with their appearance.

REFERENCES:

1. Bauch, S. (1916). Three Cases of Purpura Hemorrhagica in Chronic Tuberculosis, *Arch Intern Med* 17, 44.
2. Conti, T., & Barnet, B. (2001). The diagnostic challenge of infective endocarditis: cutaneous vasculitis leading to the diagnosis of infective endocarditis. *The Journal of the American Board of Family Practice*, 14(6), 451-456.
3. Cunha, B. A., Gill, M. V., & Lazar, J. M. (1996). Acute infective endocarditis: diagnostic and therapeutic approach. *Infectious disease clinics of North America*, 10(4), 811-834.
4. Durack, D. T., Lukes, A. S., Bright, D. K., & Service, D. E. (1994). New criteria for diagnosis of infective endocarditis: utilization of specific echocardiographic findings. *The American journal of medicine*, 96(3), 200-209.
5. Habib, G., Hoen, B., & Tornos, P. (2009). ESC Committee for Practice Guidelines Endorsed by the European Society of Clinical Microbiology and Infectious Diseases (ESCMID) and the International Society of Chemotherapy (ISC) for Infection and Cancer. Guidelines on the prevention, diagnosis, and treatment of infective endocarditis (new version 2009): the Task Force on the Prevention, Diagnosis, and Treatment of Infective Endocarditis of the European Society of Cardiology (ESC). *Eur Heart J*, 30, 2369-413.
6. Horwitz, L. D., & Silber, R. (1967). Subacute bacterial endocarditis presenting as purpura. *Archives of internal medicine*, 120(4), 483-486.
7. Jones, H. W., & Tocantins, L. M. (1933). The history of purpura hemorrhagica. *Ann Med Hist*, 5, 349-359.
8. Karchmer, A. W. (1998). Approach to the patient with infective endocarditis. *Primary cardiology*. Philadelphia: WB Saunders Company.
9. Karchmer, A.W. (1997). Infective endocarditis. In Brunwald E.editor. Heart disease: a textbook of cardiovascular medicine. Philadelphia: W B Saunders Company, 1077-103.
10. Lee, G. P. C., Chung, K. L., & Kam, C. W. (2009). An unusual case of fever with purpuric skin rash. *Hong Kong Journal of Emergency Medicine*, 16(1), 35-37.
11. Libman, E., & Friedberg, C. K. (1941). Subacute Bacterial Endocarditis, New York: Oxford University Press.
12. Mylonakis, E., & Calderwood, S. B. (2001). Infective endocarditis in adults. *New England Journal of Medicine*, 345(18), 1318-1330.
13. Osler, W. (1912). Chronic infectious endocarditis, with an early history like splenic anemia. *Interstate Med J*, 19, 103-107.
14. Stefanini, M., & Dameshek, W. (1955). The Hemorrhagic Disorders, New York, Grune & Stratton.
15. Tous-Romero, F., Delgado-Márquez, A. M., Gargallo-Moneva, V., & Zarco-Olivo, C. (2017). Cutaneous vasculitis: a presentation with endocarditis to keep in mind. *Anais Brasileiros de Dermatologia*, 92(4), 594-595.
16. Weber, F. P. (1910). *Chronic Purpura of Two Years' Duration Connected with Malignant Endocarditis, Wrongly Supposed to be Connected with Splenic Anæmia*.
17. Wintrobe, M.M. (1961). *Clinical Hematology*, ed 5, Philadelphia: Lea and Febiger.